
EDUCATION

The challenges of the higher BMI patient for the cosmetic surgeon extend to breast reduction procedures as well. Be knowledgeable about the latest research by clicking

cosmeticsurgerytimes.com/highbmi



Dr. Niamtu

The 'Diva' Facelift— Rhytidectomy for the High BMI Patient

Joseph Niamtu, III, D.M.D.
CONTRIBUTING AUTHOR

REFERENCE
Cheffe LO. Rhytidoplasty in the "pseudo-obese" patient: a group with specific characteristics and management. *Aesthetic Plast Surg.* 1990;14:179-185.

ANY SURGEON VERSED IN RHYTIDECTOMY is well aware of the challenges in operating on patients with high Body Mass Index (BMI). The BMI is calculated by dividing the body weight of an individual by the square of his or her height. Although there is variation and controversy associated with this formula, it is a useful general guideline to classify patients as underweight (less than 18.5), normal range (18.5 to 25), overweight (25 to 30) or obese (over 30). Patients in the 25 to 30 range present challenging anatomy for the facelift surgeon. These patients frequently have excess face and neck fat with or without skin excess. Not only is the subcutaneous fat abundant, but these patients also have increased accumulations of jowl fat, peri-parotid fat and submental fat (figure 1). Larger round faces and short thick necks can further accentuate the problems for facelift outcome.



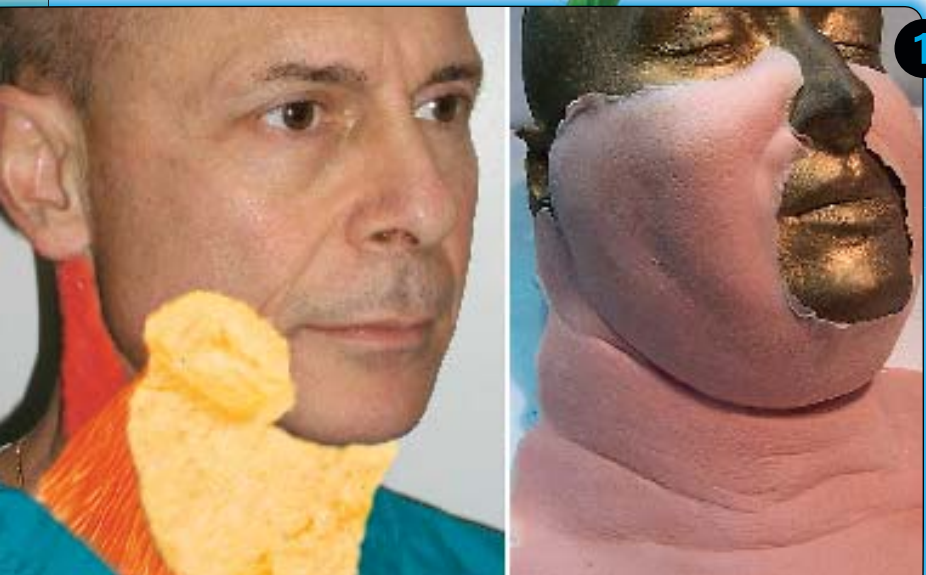Dr. Niamtu

In addition to a technical challenge, this morphology can present problems with anesthesia and recovery. Anesthetically, these patients have more potential airway problems, as some of them exhibit obstructive patterns. Deep vein thrombosis (DVT) and pulmonary embolism is also potentially more of an issue in patients with high BMI's. In the immediate post-recovery period, airway problems are also a concern, as is DVT in the recovery process. Keeping these potential problems in mind, they have not been an issue in my personal experience in this population.

SURGICAL PROCEDURE I perform most surgeries in an accredited office ambulatory center for healthy patients. My preferred anesthetic technique is IV sedation with very little narcotic and midazolam, Ketamine and propofol. My preferred means of airway support is a laryngeal mask airway (LMA), which provides a protective airway and the ability to ventilate the patient if necessary. Some anesthesiologists will also use anesthetic gasses with LMA. In my experience, these cases require extended pre- and post-auricular incisions as there is generally significant skin to be managed. A longer posterior auricular incision is used and an increased temporal pre-auricular component is also necessary (figure 2). In normal facelift patients, I prefer to make the posterior auricular incision

24

Normal fat distributions in patients with average BMI (left) vs. (right) a model of a silicone Hollywood prosthetic used to simulate increased BMI on actors which is consistent with accumulations of excess adipose tissue in patients.



All photos credit: Joseph Niamtu, III, D.M.D.

PHOTO CREDIT: PHOTODISC / DAVIES AND STARR/CULTURA / DAVID LEAHY / GETTY IMAGES

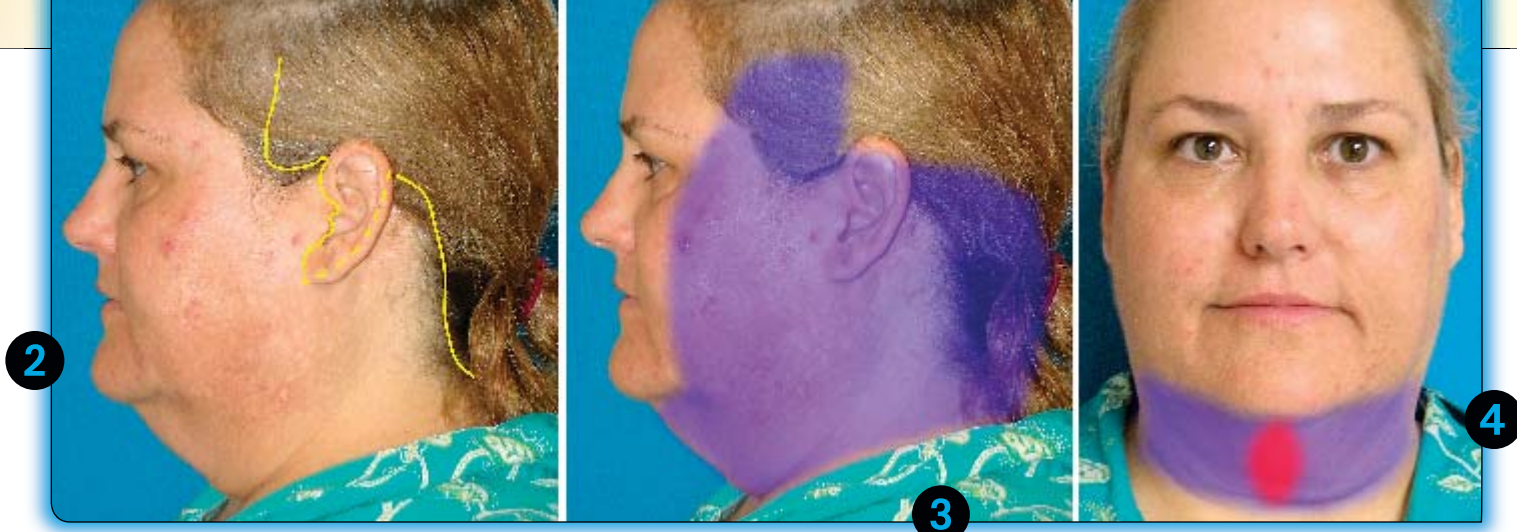

Figure 2. The yellow lines represent the extended incisions utilized in high BMI patients. Figure 3. The blue region represents the extended lipocutaneous undermining in patients with increased BMI. Figure 4. Extensive submentoplasty requires larger undermining than a patient with a lower BMI. The blue region is indicative of the undermining of the submental and lateral cervical regions. The red area represents excess midline tissue that is clamped and excised during the procedure.

high in the hairline, at or above the greatest width of the pinna, but in higher BMI patients I prefer to use a lower occipital hairline incision so as not to alter the posterior hairline. These patients also require a generally larger lipocutaneous flap dissection that extends to the lateral canthus and further in all directions than the same lift on a patient with a lower BMI (figure 3).

TECHNIQUE NUANCES Perhaps the most important step in managing patients with increased BMI is the submentoplasty. Most of these patients exhibit extremely full submental regions and although redundant skin may not be apparent pre-operatively, it can be extreme after aggressive submentoplasty.

After tumescent infiltration, an incision is made approximately 5 mm inferior to the submental crease. This slightly lower incision allows dissection above the submental crease, which frees the crease and can improve a ptotic chin. If the incision is made in the crease as many surgeons commonly do, the crease can be accentuated and contribute to a “witch’s chin” deformity.

The next step is submental and anterior cervical liposuction. Since there is abundant adipose tissue, a larger cannula is used and aggressive liposuction is performed. Since the submentoplasty will be aggressive, it is important to leave an adequate amount of subcutaneous fat on the neck flap to prevent the deformity of dermal adhesion to the platysma.

After adequate liposuction, an anterior lipocutaneous flap is raised using facelift scissors. This dissection is more generous than that performed on the average patient and extends inferior to the thyroid cartilage region, closer to the clavicles (figure 4, blue highlight). In terms of platysma management, I prefer to remove a midline ellipse of tissue. Using a large Kelly clamp, the midline tissues are secured and excised at the base of the clamp using a radiowave microelectrode (Ellman International, Oceanside, NY). After this initial excision, additional liposuction may be necessary under direct observation to visualize the medial platysmal borders.

The elliptical midline excision will uncover the fat compartment deep to the platysma and between the anterior belly of the digastric muscles. Although I

generally do not remove this deep fat in lower BMI patients, some amount of lipectomy is required in the higher BMI patient. However, care must be taken not to over-resect fat in this region, even with the heavier patient, to prevent a concavity in this region post-operatively. Judicious deep fat removal is paramount in the management of these patients.

After superficial and deep liposculpture, a midline platysmaplasty is performed. The first suture is placed at the cervicomenal region and, when tied, serves to retract the excess neck tissue in a superior/posterior vector to define the submental region. At this point, six to eight additional 2-0 braided nylon sutures are placed from the inferior extent of the platysma to the mandibular border. I feel that it is important to extend the suture line all the way to the anterior mandible to produce a “sling” effect to retract the excess tissue both superiorly and posteriorly. This retraction will fill the submental void created by the deep lipectomy to produce a smooth platysma muscle sling. I do not perform inferior platysma cutbacks as I have never experienced the “bowstring” effect described by some surgeons. In addition, I believe that the cutback serves to detract from the sling effect of the midline platysmal placement. After aggressive submentoplasty, the amount of excessive skin is impressive. Although some surgeons exclude anterior platysmaplasty in their rhytidectomy procedures, I feel that it is one of

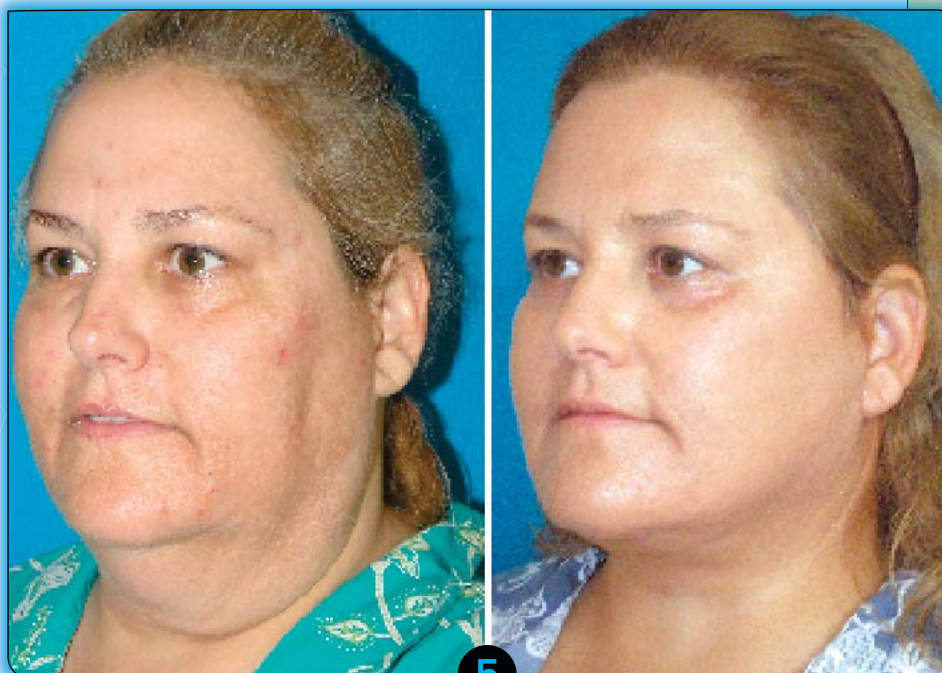the most important steps to a sculpted and long-lasting result in the anterior cervical and submental regions.

In the case of patients with microgenia, a chin implant can also dramatically improve the result by adding definition to the submental complex, as well as serving to accentuate the horizontal distance between the chin tip and the hyoid region, which also serves to reduce skin excess by effectively lengthening the horizontal mandibular length.

The next critical step in the management of the higher BMI patient is “open” liposuction of the lateral cervical regions. I use a 5 mm, single-port cannula with wall suction and remove excess fat under direct visualization on the entire lateral cervical region. Excess fat is also sculpted judiciously above the mandibular border. I then use a smaller cannula to sculpt the jowl regions which I also feel is important. After open liposculpture, the lateral platysma is generally well visualized.

SMASECTOMY In terms of SMAS management, I prefer a SMASectomy, which I believe enables the surgeon to debulk the cheek areas that are usually very heavy in this patient population. Plication techniques can produce increased bulk in the cheek regions due to the folding over of redundant tissue. I

Figure 5. This patient underwent facelift with SMASectomy and aggressive submentoplasty and chin implant.



“...I prefer a SMASectomy, which I believe enables the surgeon to debulk the cheek areas that are usually very heavy in this patient population. Plication techniques can produce increased bulk in the cheek regions due to the folding over of redundant tissue.”

IN MY HANDS



generally remove a 3 cm “D”-shaped region of SMAS from the malar region to the superior cervical region. This excision is parallel to the nasolabial fold and extends to the approximate level of the parotidomasseteric fascia.

The distal SMASectomy margin is secured at the region I call the “sweet spot.” This is the area that, when secured with a suture and retracted, will suspend the jaw and neck regions simultaneously. This initial 2-0 braided nylon suture is then secured in a superiolateral vector to the fixed SMAS over the parotid gland. Next, six to eight additional 2-0 braided nylon sutures are placed from the malar region to the superior cervical region. When each suture is tightened, the surgeon can appreciate elevation and suspension of the mid-face, the jaw and the cervical regions. This is one of the powerful aspects of the SMASectomy technique.

The next step is to suspend the lateral platysma border to the mastoid region. Some surgeons feel that this maneuver only serves to pull against the midline platysma plication, but I feel that it enhances the sling effect to pull the cervical and submental regions up and back, which produces a profound long-lasting aesthetic result. I generally place three to four, 2-0 braided nylon sutures from the inferior border of the mandible to the inferior cervical region until no additional suspension is appreciated.

The final step, like all facelifts, is skin flap suspension and removal. Due to the aggressive submentoplasty, there is generally extreme skin excess, and care must be used in placing the key retention sutures to make sure that the vector of skin pull properly addresses the excess submental skin. Failure to pay attention to this region can result in post-surgical submental skin excess. It is not uncommon for me to place the key sutures, trim some excess skin and replace the key sutures to affect a different vector of pull as the procedure progresses. After the proper vector is achieved and the neck is tight, skin removal proceeds like conventional rhytidectomy.

I close the hair-bearing regions with staples and the remainder of the incisions with resorbable 4-0 and 5-0 gut sutures. The extent of improvement is obvious at the end of the procedure. After the hair is washed, a “jaw bra”-type dressing is placed with fluff gauze over the undermined flaps. On the average facelift patient, I remove this dressing at 24 hours, but on patients with higher BMI, I

leave the dressing in place for about five days, as these larger submentoplasties are more subject to seroma formation, which can affect the final result.


DISCUSSION Some surgeons refuse to operate on patients with high BMI unless they lose weight. Although this would be an optimum situation, most patients in this category will not permanently drop excess poundage. I have no problem operating on patients with high BMI and have had some of my most dramatic results in this group. I do counsel them on the advantages of pre-operative weight loss and the drawbacks of performing rhytidectomy on a round face. One potential problem is that performing aggressive submentoplasty on a patient with a full, round face is that the neck will be flat and the remainder of the face will remain round. This has never been a problem with my patient population, but it is important to explain all the pluses and minuses of facelift surgery on a patient with a very full face and neck. The informed consent process must include these considerations.

CONCLUSIONS Patients with high BMI present a challenge for the facelift surgeon. Many surgeons refuse to operate on this population unless these lose weight pre-operatively. I personally feel that this is sometimes an excuse for the surgeon not to have to deal with a difficult case and serves to put the patient off. I have operated on numerous patients who were turned down by other surgeons due to their high BMI and have had excellent results with happy patients. This procedure, in multiple cases, has served to instill self-confidence in these patients and given them the drive and desire to lose weight to match their facial improvement. I have seen these patients transform from a state of “I am over-the-hill due to my weight and hopeless” to a state of improved self-esteem where they now wear makeup, are more attuned to their clothing selection, and have the drive and desire to pursue generalized weight loss. I feel that operating on this population can serve as a positive stimulus in their life to improve their lifestyle and health. ◀


Joseph Niamtu, III, D.M.D., a fellow of the American Academy of Cosmetic Surgery and board certified by the American Board of Oral and Maxillofacial Surgery, specializes exclusively in cosmetic facial surgery in Richmond, Virginia.

ASSI
Perma Facial Implant™
Tunneler Passers
and Forceps


The ASSI® Perma Facial Implant Tunneler and Perma Facial Implant Forceps were specifically designed to be used with the Perma Facial Implant. The Large and Small ASSI Implant Tunneler Passers are ideally suited for passage through the subcutaneous tissue to the jaw, and securely grasp the Perma Facial Implant. The unique design of the jaws on both the ASSI Implant Tunneler Passers and ASSI Perma Facial Implant Forceps facilitates easy re-grasping of the Perma Facial Implant without causing trauma to the implant.




ADULT/CHILD
Perma Facial Implant Tunneler Passer Small
150% ORL. SPECIAL ORAL JAW TOO




ADULT/CHILD
Perma Facial Implant Tunneler Passer Small




ADULT/CHILD
Perma Facial Implant Tunneler Passer Large
100% ORL. SPECIAL ORAL JAW TOO




ADULT/CHILD
Perma Facial Implant Tunneler Passer Large




ADULT/CHILD
Perma Facial Implant Forceps Straight
75 ORL. SPECIAL ORAL JAW TOO



ADULT/CHILD
Perma Facial Implant Forceps Straight



ADULT/CHILD
Perma Facial Implant Forceps Angled
75 ORL. SPECIAL ORAL JAW TOO



ADULT/CHILD
Perma Facial Implant Forceps Angled

ASSI
JEWELRY SPECIALTY LABORATORIES
For diamond jewelry performance™

Accurate surgical & ophthalmic instruments corporation
390 Sisson Drive, Woburn, MA 01896
800.645.3069 508.338.2578 fax: 508.977.4948 web: 608.255.9370
www.accuracyinstruments.com